

Percutaneous Cementoplasty

(PC, vertebral packing, vertebroplasty)

1) Introduction

Percutaneous Cementoplasty (PC, vertebral packing, vertebroplasty) with acrylic glue (polymethylmethacrylate: PMMA) is a procedure aimed at preventing vertebral body crushing and pain in patients with pathological vertebral bodies. Percutaneous cementoplasty seems to be promising in pain therapy for patients with bone failure.

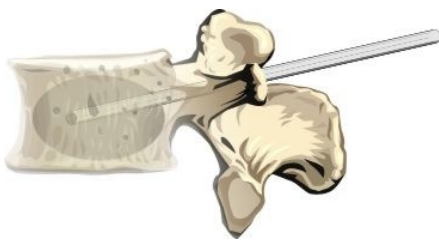

Fig 1: principle

2) Principle

The pain reducing effect of cement cannot be explained by the consolidation of the pathological bone alone. In fact, good pain relief is obtained after injection of only 2 ml of methyl methacrylate in metastasis. In these cases the consolidation effect is minimal. The methyl methacrylate is cytotoxic due to its chemical and thermal effect during polymerization. The temperature during polymerization is high enough to produce coagulation of the tumoral cells. Therefore, good pain relief can be obtained with a low volume of glue.

3) Indications and Contraindications

Indications

Percutaneous injection of acrylic glue is proposed in :

- Symptomatic vertebral angioma.
- Painful vertebral body tumors (particularly metastasis and myeloma). The best indications are painful vertebral body tumors, particularly when there is a risk of compression fracture.
- Severe painful osteoporosis with loss of height and/or with compression fractures of the vertebral body.

Contraindications

- Hemorrhagic diathesis
- Infection
- Lesions with epidural extension require careful injection to prevent epidural overflow and spinal cord compression by the cement.

4) Technique

Technique overview

The procedure is performed under local anesthesia usually combined with neuroleptanalgesia. The patient is placed in prone position for lumbar level and in supine position for cervical level. A 15-gauge needle is used in cervical level, a 10-gauge needle in thoracic and lumbar level. We always use dual guidance : CT and C-arm fluoroscopy. The entry point and the pathway are determined by CT, avoiding the nerve root and visceral structures. The needle is safely guided under CT.

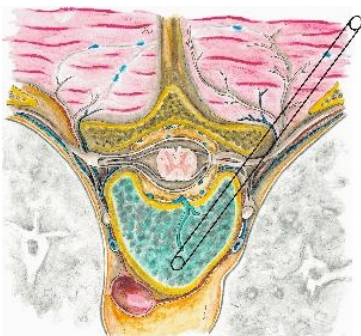


Fig 2 : PC axial plane

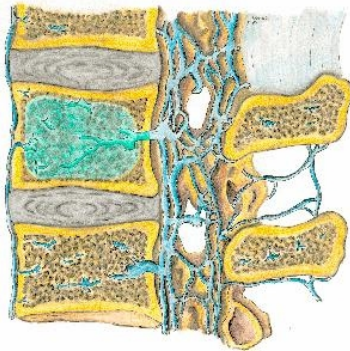


Fig 3: PC sagittal plane

Once the needle is in the optimal position, the imaging mode is switched to fluoroscopy. The acrylic cement mixed with tantalum (to increase radio-opacity) has to be injected during its pasty polymerization phase to prevent distal venous migration. The injection of glue is carefully controlled under strict lateral fluoroscopy. The injection of glue is stopped whenever an epidural or paravertebral opacification is observed.

Material

- 10-gauge needle for thoracic and lumbar spine and a 15-gauge needle for cervical spine
- Surgical hammer
- Acrylic glue (methyl methacrylate Howmedica®, Microlok®, Simplex® or Palacos® low viscosity)
- Pressure syringe (Optimed®) to facilitate the injection of this viscous glue
- and 2g tantalum or tungsten (acrylic cement is not radio-opaque enough)
- Sterile drapes, tampons
- 22-gauge needle for anesthesia, scalpel
- Iodine, 1% lidocaine

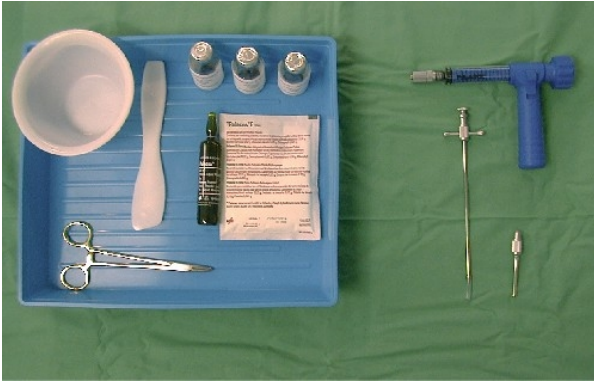


Fig 4: PC material acrylic glue, pressure syringe, 3g tantalum, 10-g needle

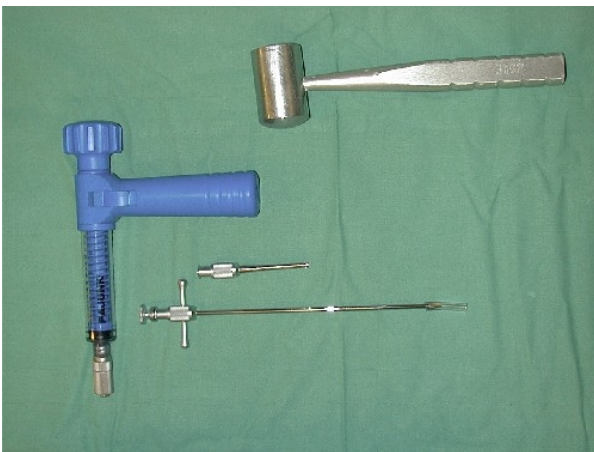


Fig 5: PC material surgical hammer, pressure syringe, 10-g needle

Focus on dual guidance

Dual guidance

Percutaneous cementoplasty, like other interventional procedures, is usually performed with a single imaging technique: fluoroscopy or CT, both of which have advantages and drawbacks. Fluoroscopy offers multiple planes and direct imaging with the disadvantages of poor soft-tissue contrast and non-negligible radiation exposure for both patient and operator. CT is well-suited for precise interventional needle guidance because it provides

good visualization of bone and surrounding soft tissues. It also avoids damage to adjacent vascular, neurological, and visceral structures. The disadvantages of this method are single-plane and delayed imaging.

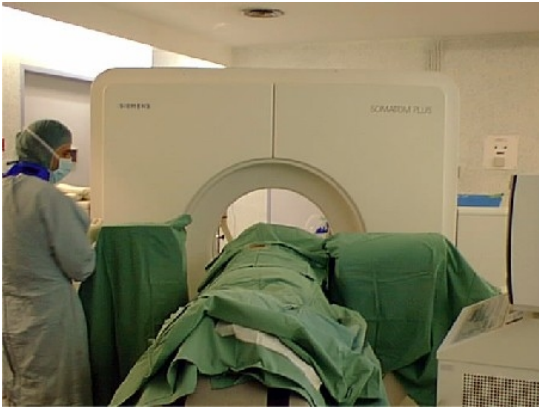

Fig 6: dual guidance CT and fluoroscopy

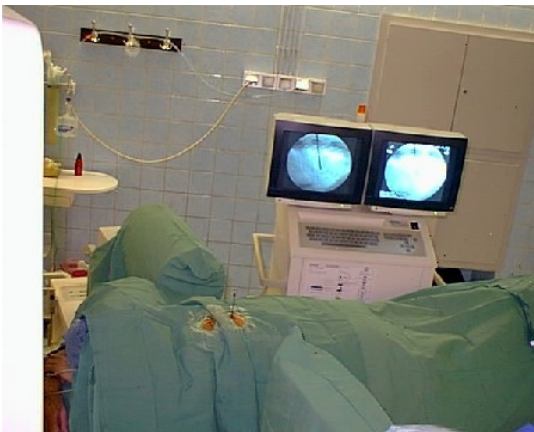


Fig 7: dual guidance fluoroscopy and CT

To address these concerns on a routine basis, a combination of CT and fluoroscopy for interventional procedures has been recommended. For fluoroscopy, a mobile C-arm is used, positioned in front of the CT-gantry. By using a rotating fluoroscope and CT, the structure to be punctured can be visualized three dimensionally and with exact differentiation of anatomic structures, which in many cases is not possible with fluoroscopy alone. Two mobile monitors were placed in front of the physician, displaying the last stored image and the fluoroscopic image. The operator can switch from CT to fluoroscopy and vice versa at any time.

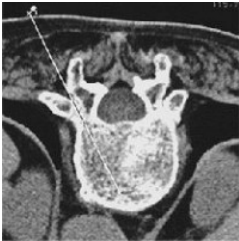

Fig 8: CT pathway

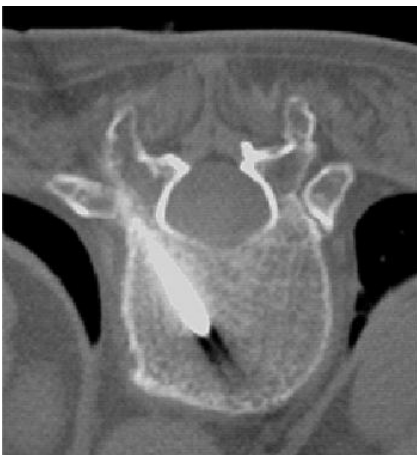

Fig 9: CT control

Anesthesia Local anesthesia

The procedure is performed under local anesthesia usually combined with neuroleptanalgesia. The skin, subcutaneous layers, muscles and the periosteum are infiltrated by local anesthesia (1% lidocaine) with a 22-gauge needle, 9 cm long.

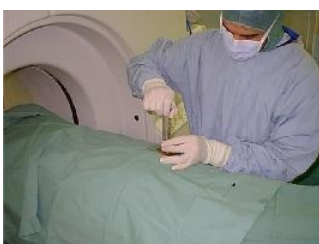

Fig 10: Local anesthesia

Puncture

After positioning the patient, under neuroleptanalgesia and local anesthesia, a 10 to 15-gauge trocar needle is introduced into the vertebral body. Different approach routes can be selected: the anterior route for cervical level, the transpedicular and intercostovertebral route for the thoracic level, the posterolateral and the transpedicular route for the lumbar level.

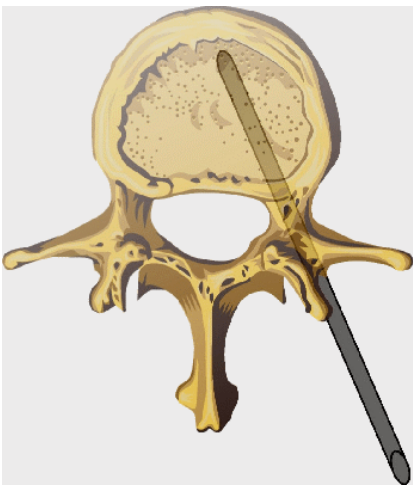


Fig 11: Transpedicular

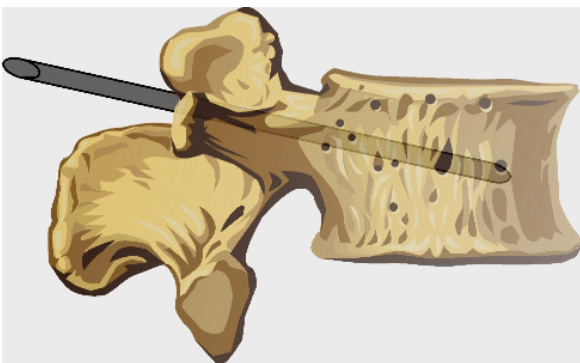


Fig 12: Transpedicular route

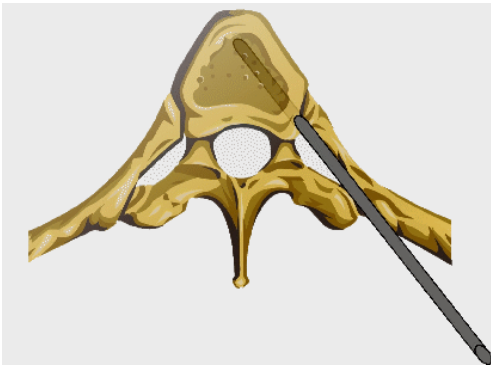


Fig 13: Intercostovertebral route

The needle is guided safely under CT. Cortical perforation requires the aid of a surgical hammer. When the needle is in the optimal position (needle tip in the anterior third of the vertebral body), the imaging mode is switched to fluoroscopy.

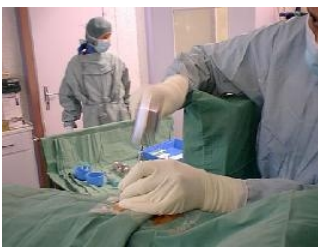


Fig 14: puncture

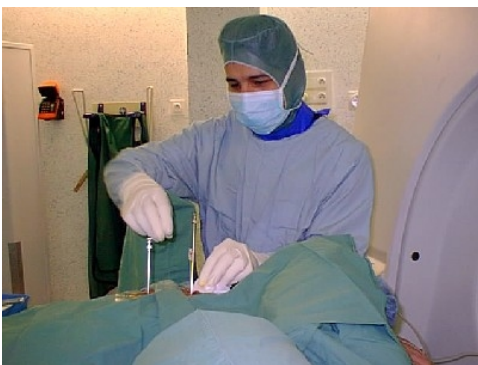

Fig 15: surgical hammer

Puncture demonstration

Play animation : vertebral puncture. Transpedicular route ; MEPG4

See : vert-pun-agif1.mp4 

Preparation of the cement

A package of methyl methacrylate (Howmedica®, Microlok®, Palacos or Simplex®) low viscosity is composed of a packet of 40 g powder and a tube of 20 ml fluid monomer. The acrylic glue is prepared by mixing 20 g of powder (half of the packet) and 10 ml of fluid monomer.

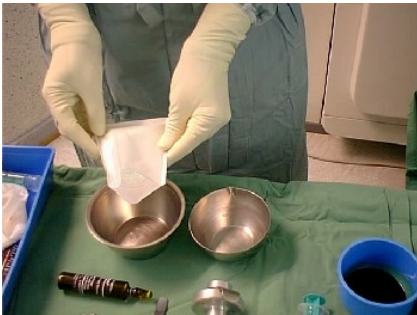

Fig 16: PMM powder + monomer

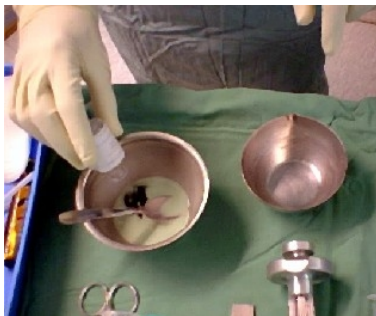

Fig 17: PMM + tantalum powder

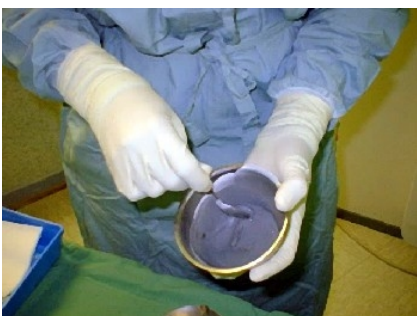

Fig 18: End product after mixing

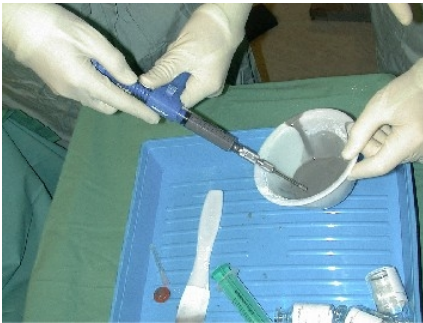

Fig 19: Syringe filling

The cement is prepared by mixing 20 g of polymethylmethacrylate (PMM) powder (half a packet) and 10 ml of fluid monomer. Because the cement is not sufficiently radiopaque, 2 g of tantalum is added to the mixture. During the first 30-50 seconds after mixing, the glue is thin but then becomes pasty. The acrylic cement has to be injected during its pasty polymerization phase to prevent distal venous migration. Two to eight milliliters of acrylic glue are injected using a pressure syringe (Optimed®) to facilitate the injection of this viscous mixture. At this stage, the intervention has to be performed quickly because the glue begins to thicken after three minutes and any further injections become impossible.

Injection of the cement

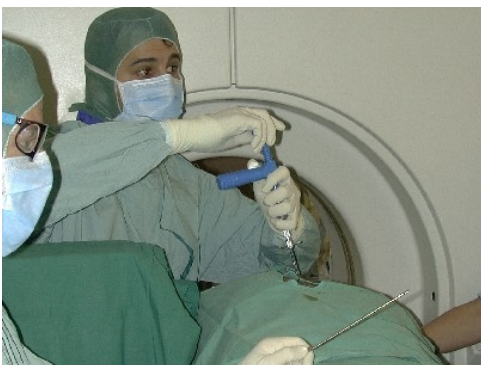

Fig 20: Injection of the cement

This phase of the procedure is controlled under strict lateral fluoroscopy. The injection of acrylic glue is stopped immediately whenever an epidural or paravertebral opacification is observed in order to prevent spinal cord compression. When vertebral filling is insufficient, a contra-lateral injection is suggested in order to complete the filling. After the vertebral filling, the mandrin of the needle is replaced and the needle is removed before the cement begins to set. Six to seven minutes after mixing, the methyl methacrylate begins to harden. During this hardening time, the methyl methacrylate becomes hot (+/- 90 °C). The patient should be under neureleptanalgesia to control pain. Monitoring of the arterial pressure is necessary during the procedure because methyl methacrylate injections can induce brief drops in arterial pressure. Total procedure time ranges from 20 to 50 minutes. In patients with osteoporosis and symptomatic hemangioma, an optimal filling (2.5 - 4 ml) of the vertebral body is required to obtain both effects of percutaneous vertebroplasty : consolidation and pain relief. In patients with tumoral pathologies, percutaneous cementoplasty is usually performed for excruciating pain. In these cases, a low volume (1.5 - 2.5 ml) of acrylic glue allows good pain relief.

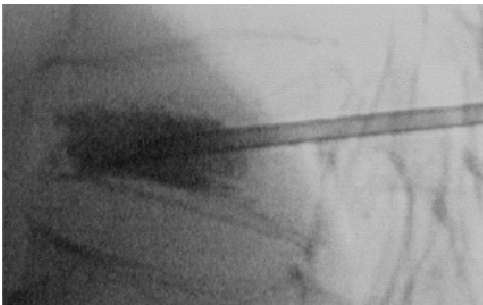


Fig 21: Injection of the cement under fluoroscopy

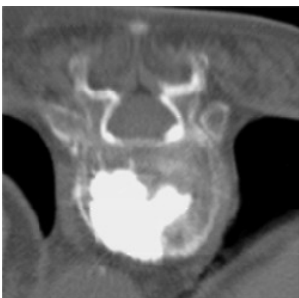

Fig 22: CT control

5) Complications

Complications

- The major complications are cement leaks.
- The secondary complication is infection. To avoid this complication, severe sterility during the intervention is mandatory.
- Temporary pain can be observed after the procedure. The patients were usually free of symptoms after 24 hours. The post-procedural pain is usually proportional to the volume of glue injected. The majority of these patients had good packing of the vertebral body with more than 4 ml of acrylic glue injected.
- The risk of allergic accidents and hypertension is limited in these procedures, because the quantities of acrylic glue injected in percutaneous cementoplasty are far less than those used in orthopedic surgery.

Cement leaks

- Cement leaks toward epidural veins, epidural space and neural foramina: the major complication during acrylic glue injection is epidural overflow of methyl methacrylate with spinal cord compression in vertebral cementoplasty: this risk is minimized by monitoring the bone filling by a high-quality fluoroscopy unit, by adequate radiopacity (tantalum) of acrylic glue. Radiculopathy is the major risk with neural foramina leaks. In our series, 3 complications occurred immediately after cementoplasty with the filling of an epidural vein and neural foramina causing intercostal neuralgia. This complication can be successfully treated by a series of intercostal steroid infiltrations. In case of complication, orthopedic or neurosurgical support should be available. Epidural vein filling does not systematically cause neuralgia.

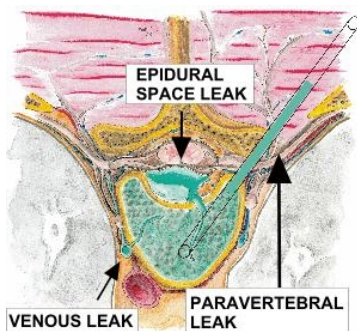


Fig 21: axial plane, leaks

- Cement leaks towards the disk. These leaks are usually without clinical consequence, however these leaks may increase the risk of adjacent vertebrae collapse.
- Venous leak into perivertebral veins can lead to pulmonary cement embolism. In our series, an asymptomatic pulmonary embolism was detected in two cases. In both cases, paravertebral venous opacification was observed. To avoid major pulmonary infarction, the glue should be injected slowly during its pasty polymerization phase under fluoroscopy control, and the injection should immediately be stopped if a venous leak is observed.
- Cement leaks into paravertebral soft tissues have no clinical significance.
- In one case, the control CT scan showed a leak of acrylic cement into an intercostal artery. This leak was asymptomatic.

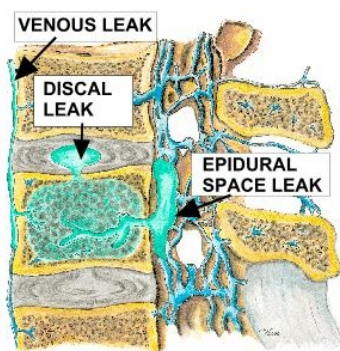


Fig 22: sagittal plane, leaks

Diskal leak

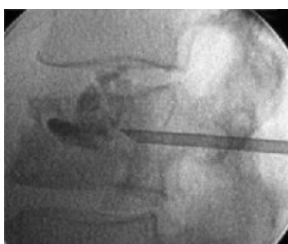

Fig 23: fluoroscopy diskal leak

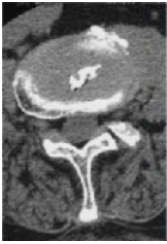

Fig 24: CT diskal leak

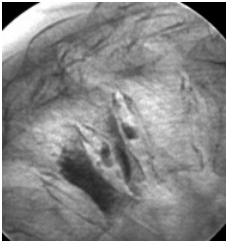


Fig 25: fluoroscopy diskal leak

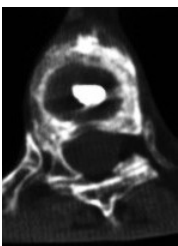


Fig 26: CT diskal leak

Venous leak

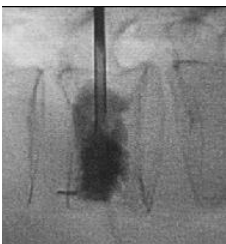

Fig 27: fluoroscopy venous leak

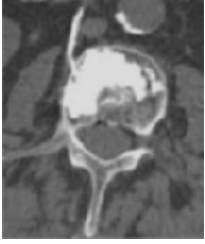

Fig 28: CT venous leak

Pulmonary cement embolism secondary to venous leak

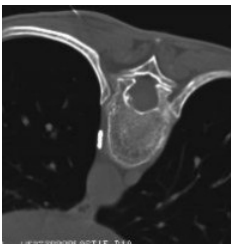


Fig 29: CT venous leak

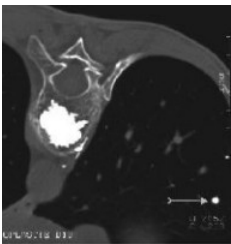


Fig 30: CT pulmonary cement embolism (arrow)

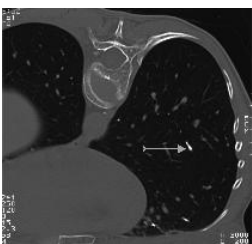


Fig 31: CT pulmonary cement embolism (arrow)

Cement leaks toward epidural space

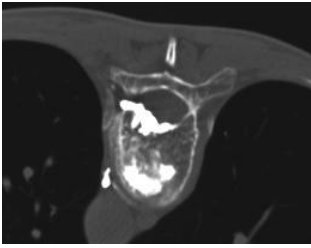


Fig 32: CT anterior epidural space leak

Cement leaks toward epidural space causing intercostal neuralgia

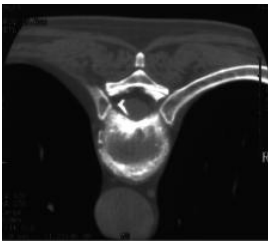


Fig 33: CT epidural space leak

6) Results

Results Overview

From 1990 to 1999 we performed percutaneous cementoplasty in 187 patients : indications included severe painful osteoporosis (105 patients), vertebral tumors (myeloma and metastasis 69 patients), symptomatic hemangiomas (11 patients), and postchirurgical decompression (2 patients). A total of 289 vertebral bodies were injected (mean of 1.54 vertebra/patient). The average volume of cement injected was 2.8 ml (ranging from 1.8 to 6.5 ml). The analgesic effect appeared within 12 to 48 hours after procedure. The results were evaluated according to the reduction of opiate analgesic doses. Satisfactory results (pain score > 2) were obtained in 79% of the patients . An analgesic score of 3 or higher was achieved in 71% of the patients. Percutaneous cementoplasty is a successful technique for pain management and consolidation of pathologic vertebral bodies. The most critical elements for successful vertebroplasty are proper patient selection, correct needle placement, good timing of cement injection, strict fluoroscopy control of injection, and operator's experience. The good pain relief obtained with this technique is not correlated with the volume of glue injected, especially in metastasis where 1.5 ml of glue is usually enough to reduce considerably the patient's pain.

ANALGESIC SCORE DEFINITION

Score	Definition
1	little or no relief
2	moderate relief (25% to 50% reduction of analgesic doses)
3	very good but incomplete relief (75% reduction of analgesic doses)
4	complete relief

Detailed Results

Score	Number of patients	%
greater than or equal to 2	82	78

OSTEOPOROSIS (105 CASES)

Satisfactory results were obtained in 78% of the cases based on the reduction of analgesics doses. Maximum follow-up was 7 years (average 2,7 years).

Score	Number of patients	%
greater than or equal to 2	57	83

VERTEBRAL TUMORS (69 CASES)

Satisfactory results were obtained in 85% of the cases based on the reduction of opiate doses. Maximum follow-up was 1,2 years (average 7 months).

Score	Number of patients	%
greater than or equal to 2	8	73

HEMANGIOMAS (11 CASES)

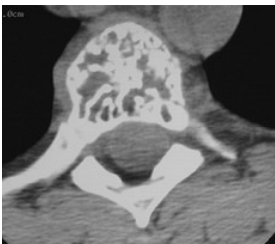
Satisfactory results were obtained in 78 % of the cases based on the reduction of opiate doses. Maximum follow-up was 6 years (average 3,8 years).

In 3 cases with epidural extension with neurologic complications, first percutaneous vertebroplasty was performed and the surgical intervention was carried out for epidural decompression in a second phase.

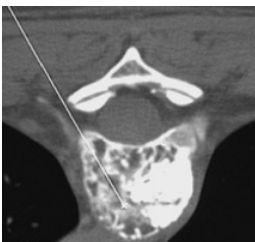
7) Cases

Case 1 : Percutaneous cementoplasty. intercostovertebral route.

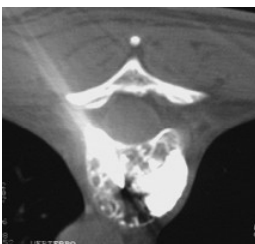
Indication: aggressive vertebral angioma. Bilateral approach. No complications.



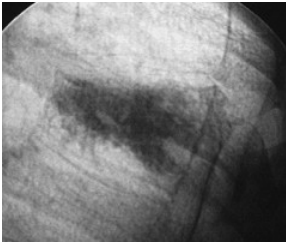
CT : Vertebral angioma



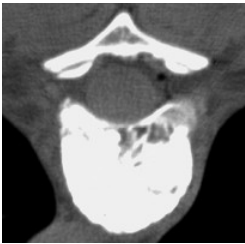PC : CT pathway



PC : Puncture CT control

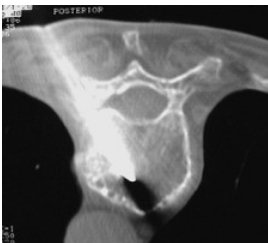

PC : Fluoroscopy control

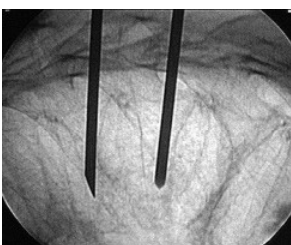

PC : CT control

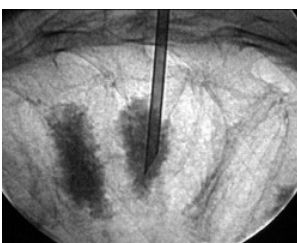Case 2 : Percutaneous cementoplasty at five levels. Intercostovertebral route. Indication : severe osteoporosis with loss of height and with several compression fractures of vertebral bodies. No complications



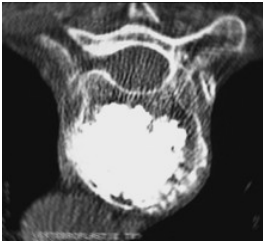
PC : Puncture CT control



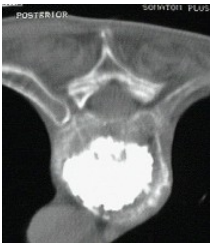PC : Puncture fluoroscopy control



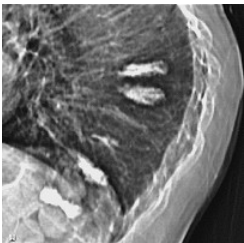PC : Cement injection fluoroscopy control



PC : CT control

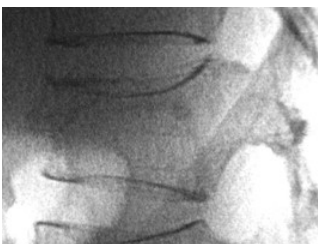

PC : CT control

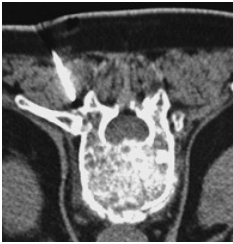

PC : Fluoroscopy control

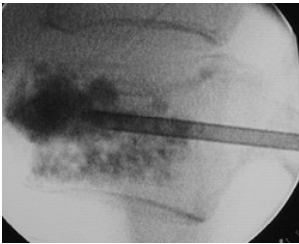
**Case 3 : Percutaneous cementoplasty. Intercostovertebral route.
Indication : severe osteoporosis. No complications**



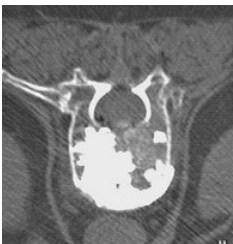
Fluoroscopy : severe osteoporosis



PC : vertebral puncture CT control

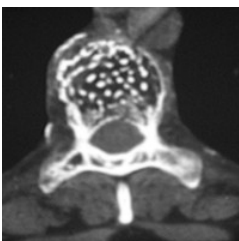


PC : Cement injection fluoroscopy control

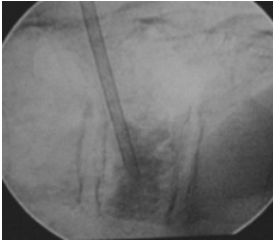


PC : CT control

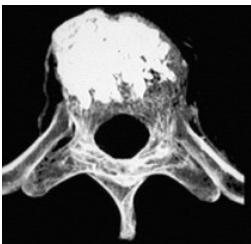
Case 4 : Percutaneous cementoplasty. Transpedicular route. Indication : vertebral angioma



CT vertebral angioma

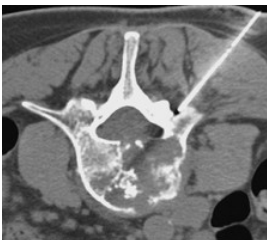


PC: Cement injection fluoroscopy control

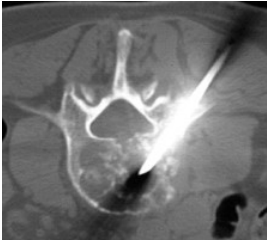

PC : CT 3D reconstruction

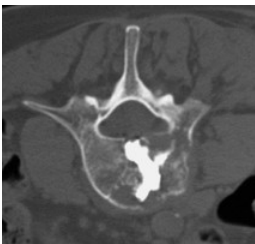
**Case 5 : Percutaneous cementoplasty : injection of 3.5 ml of glue.
Transpedicular route. Indication : painful metastases. Good pain relief,
no complications.**



PC : Local anesthesia CT control

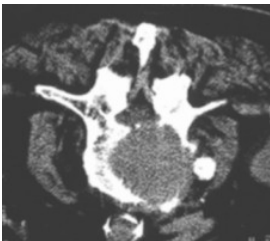

PC : Puncture CT control

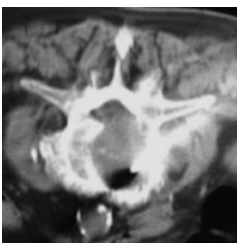


PC : CT control

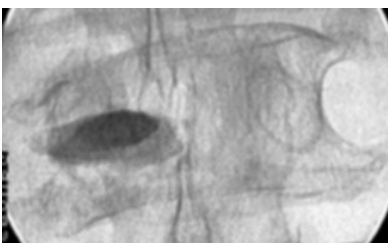
**Case 6 Vertebroplasty : injection of 2.5 ml of glue. Posterolateral route.
Indication : painful metastases. No complications.**



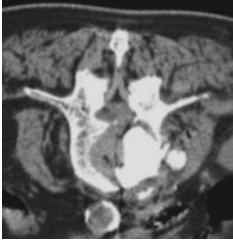
CT Osteolytic metastasis



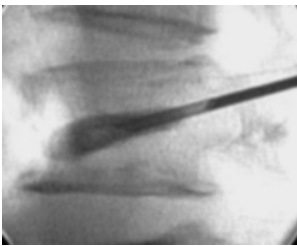
PC : Puncture CT control



PC: Cement injection fluoroscopy control

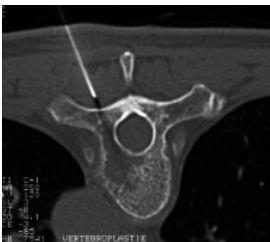

PC : CT control

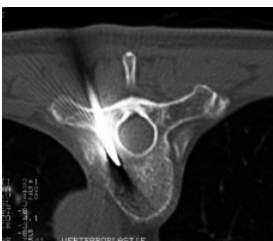

PC: Cement injection fluoroscopy control

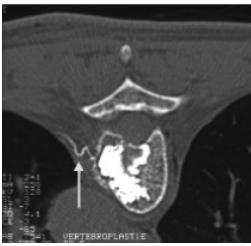
Case 7 : Percutaneous cementoplasty. Transpedicular route. Indications : osteolytic hypervascular breast cancer metastasis. Cement leak in the intercostal artery



PC : Local anesthesia CT control

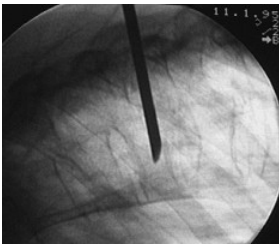


PC : Puncture CT control

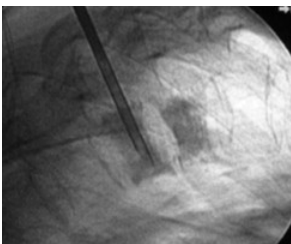


PC : CT control, intercostal artery leak (arrow)

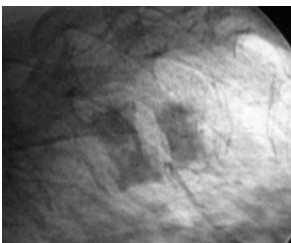
Case 8 : Percutaneous cementoplasty at two levels. Intercostovertebral route. Indication : severe osteoporosis. Minimal veinous leak



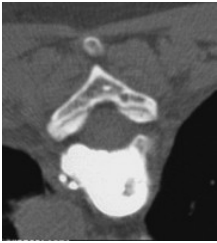PC : Puncture fluoroscopy control



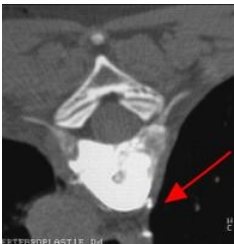PC : Cement injection under fluoroscopy



PC : Fluoroscopy control

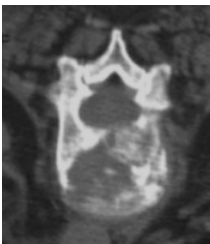


PC : CT control venous leak

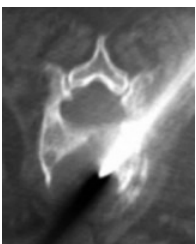

PC : CT control minimal

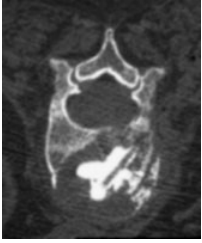**Case 9 Percutaneous cementoplasty : injection of 3.5 ml of glue.
Intercostovertebral route. Indication : painful metastases. Good pain
relief, no complications.**



CT osteolytic metastasis



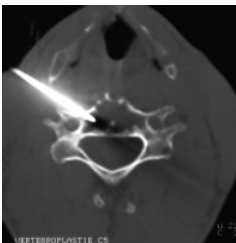
PC : Puncture CT control



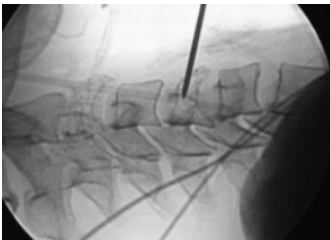
PC : CT control

Case 10 : Percutaneous cementoplasty at C4 level, anterior route.

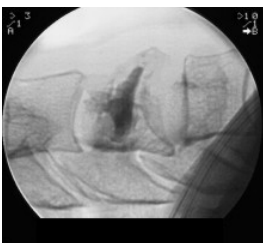
Indication : myeloma. Minimal discal leak C3-C4



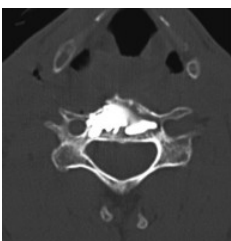
PC : Puncture CT control



PC : Puncture fluoroscopy control

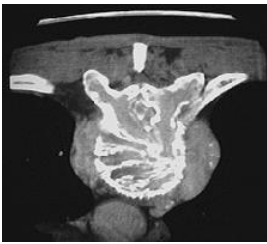


PC : Fluoroscopy control, discal leak

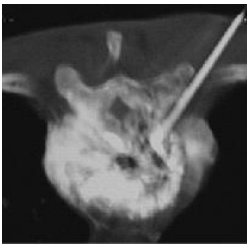


PC : CT control

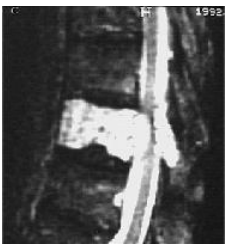Case 11 Percutaneous cementoplasty. Indication : aggressive vertebral angioma. Intercostovertebral pathway. First percutaneous vertebroplasty was performed and the surgical intervention was carried out for epidural decompression in a second phase.



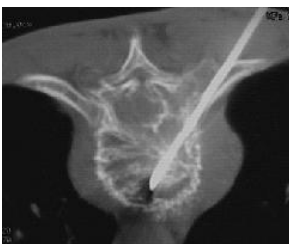CT : aggressive angioma



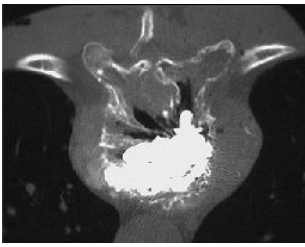
CT : venography



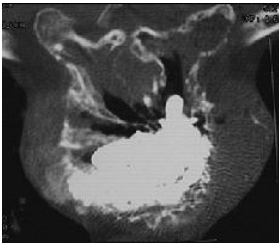
MRI : aggressive angioma with spinal cord compression



CT : aggressive angioma, puncture

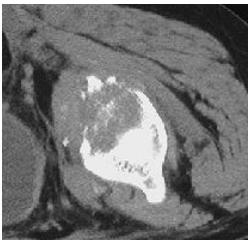


PC : CT control

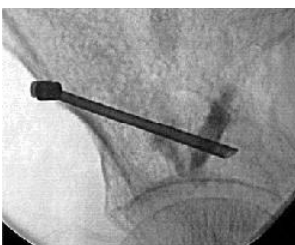

PC : CT control

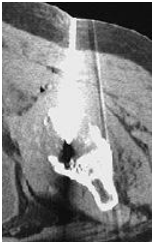Case 12 : Percutaneous acetabular cementoplasty. Same technique as vertebroplasty.
Indication : painful metastases. Good pain relief, no complications.



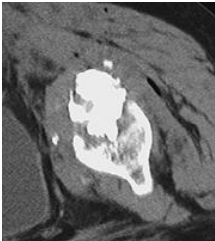
CT : osteolytic metastasis of acetabulum



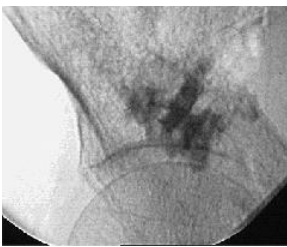Fluoroscopy : osteolytic metastasis of acetabulum



CT : acetabular cementoplasty

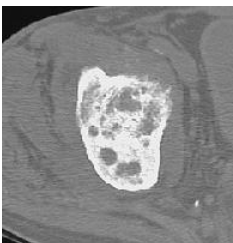


CT control : acetabular cementoplasty

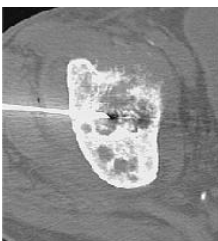


Fluoroscopy : acetabular cementoplasty

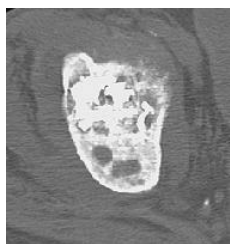
Case 13 : Percutaneous acetabular cementoplasty. Same technique as vertebroplasty.
Indication : painful metastases. Good pain relief, no complications.



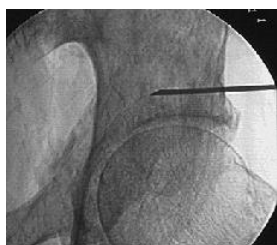CT : osteolytic acetabular metastasis



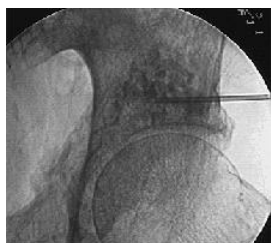Puncture : CT control



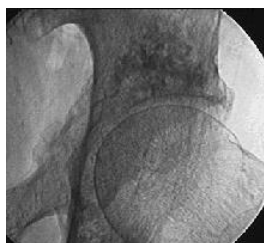Acetabular cementoplasty : CT control



Puncture : fluoroscopy control



Injection : fluoroscopy control



Acetabular cementoplasty : fluoroscopy control